

# Biomechanical Consequences of Adding Plantar Fascia Release to Metatarsal Osteotomies: Changes in Forefoot Plantar Pressures

Umur Aydogan, Evan P. Roush, Blake E. Moore, Seth H. Andrews, Gregory S. Lewis

Department of Orthopaedics and Rehabilitation, Penn State Hershey Bone and Joint Institute, Penn State Milton S. Hershey College of Medicine, Hershey, Pennsylvania

Received 26 October 2015; accepted 7 June 2016

Published online in Wiley Online Library (wileyonlinelibrary.com). DOI 10.1002/jor.23331

**ABSTRACT:** Destruction of the normal metatarsal arch by a long metatarsal is often a cause for metatarsalgia. When surgery is warranted, distal oblique, or proximal dorsiflexion osteotomies of the long metatarsal bones are commonly used. The plantar fascia has anatomical connection to all metatarsal heads. There is controversial scientific evidence on the effect of plantar fascia release on forefoot biomechanics. In this cadaveric biomechanical study, we hypothesized that plantar fascia release would augment the plantar metatarsal pressure decreasing effects of two common second metatarsal osteotomy techniques. Six matched pairs of foot and ankle specimens were mounted on a pressure mat loading platform. Two randomly assigned surgery groups, which had received either distal oblique, or proximal dorsiflexion osteotomy of the second metatarsal, were evaluated before and after plantar fasciotomy. Specimens were loaded up to a ground reaction force of 400 N at varying Achilles tendon forces. Average pressures, peak pressures, and contact areas were analyzed. Supporting our hypothesis, average pressures under the second metatarsal during 600 N Achilles load were decreased by plantar fascia release following proximal osteotomy ( $p < 0.05$ ). However contrary to our hypothesis, peak pressures under the second metatarsal were significantly increased by plantar fascia release following modified distal osteotomy, under multiple Achilles loading conditions ( $p < 0.05$ ). Plantar fasciotomy should not be added to distal metatarsal osteotomy in the treatment of metatarsalgia. If proximal dorsiflexion osteotomy would be preferred, plantar fasciotomy should be approached cautiously not to disturb the forefoot biomechanics. © 2016 Orthopaedic Research Society. Published by Wiley Periodicals, Inc. J Orthop Res

**Keywords:** plantar fascia; fasciotomy; metatarsalgia; metatarsal osteotomy

The term metatarsalgia describes a painful condition underneath the metatarsal heads, most commonly the second metatarsal.<sup>1</sup> Although it can arise from various pathologies including rheumatoid arthritis or iatrogenic conditions, the most common cause is increased plantar pressure underneath the metatarsal head. A long second metatarsal, which destroys the normal metatarsal parabola, is commonly suspected as a cause for this condition.<sup>2</sup>

When conservative treatment options fail, surgical treatment may be warranted. Restoring the normal metatarsal parabola and normalizing the forefoot pressure distribution are the main surgical aims.<sup>3</sup> Currently, distal metatarsal oblique shortening osteotomy is commonly used for surgical treatment of metatarsalgia.<sup>4,5</sup> Multiple modifications of this osteotomy have been described to decrease its complication of floating toe.<sup>6</sup>

When metatarsalgia is associated with additional conditions like pes cavus or plantar fasciitis, simultaneous metatarsal osteotomy, and plantar fascia release may be indicated.<sup>7,8</sup> Plantar fascia tightness is also accused for secondary metatarsalgia by some authors and sole plantar fascia release was advocated for the treatment.<sup>9</sup> The plantar fascia acts as a mechanical connection between the calcaneus and all five metatarsal heads, creating a biomechanical arch supporting

the bones of the foot.<sup>10</sup> There is controversial evidence in the literature on the effects of plantar fascia release on foot mechanics.<sup>11</sup> Plantar flexed metatarsals, due to over pull of contracted plantar fascia, can also cause metatarsal overload as commonly seen in Charcot-Marie-Tooth disease. When added to the complex reconstruction, plantar fasciotomy and metatarsal dorsiflexion osteotomy are shown to be effective for this condition.<sup>12</sup> An increased plantar metatarsal pressure has also been shown to be an etiologic factor for diabetic plantar ulcerations. A recent study showed that, selective plantar fascia release can lead to healing of neuropathic forefoot ulcers in diabetic patients.<sup>13</sup> Although plantar fascia release's effect on forefoot loading has previously been studied, to our knowledge there are no studies on the effect of PF release on forefoot loading in the presence of common metatarsal osteotomies.

The Achilles tendon has a close relation to plantar fascia both anatomically and biomechanically.<sup>14,15</sup> An increase in the tensile force in Achilles tendon has been reported to cause an increase on the tensile strain and tensile force in the plantar fascia.<sup>16</sup>

In this study, we hypothesized that adding plantar fasciotomy to metatarsal osteotomies would further decrease the plantar metatarsal pressures by altering the forefoot biomechanics under different Achilles tendon tensions. To test our hypothesis, we measured the metatarsal plantar pressure distribution of cadaveric feet, which had previously received metatarsal osteotomies, before and after plantar fascia release. Two different common metatarsal osteotomies were tested because of the potential dependence of fascia-release effects on the type of

Grant sponsor: National Center for Advancing Translational Sciences; Grant number: KL2 TR000126.

Correspondence to: Gregory Lewis (T: +717 531 5244; F: +717 531 0349; E-mail: greglewis@psu.edu) and Umur Aydogan (T: +717 531 7315; E-mail: Uaydogan@hmc.psu.edu)

© 2016 Orthopaedic Research Society. Published by Wiley Periodicals, Inc.

osteotomy performed beforehand. Achilles tendon condition was also varied due to its relation with plantar fascia.

## METHODS

### Specimens and Loading Setup

A total of six matched pairs of fresh frozen cadaver feet specimens were obtained from four female and two male donors with a mean age of 51.3 (range 47–58). The selected specimens were free of any known surgical operation, scar or arthritic condition. They were then assigned randomly to modified distal oblique metatarsal osteotomy or proximal oblique osteotomy with equal numbers of left and right feet in each group. The biomechanical effects of the osteotomies themselves without plantar fascia release are described in a separate report.<sup>17</sup>

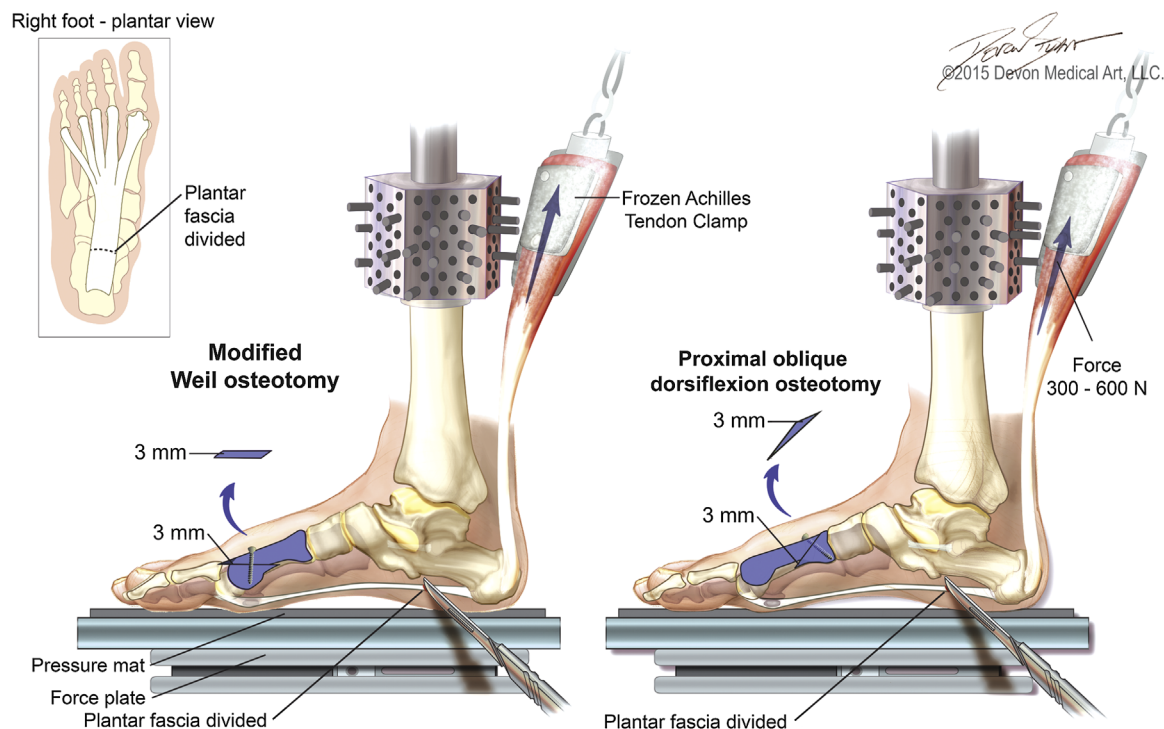
All specimens were prepared by exposing the proximal tibia and then potting into a section of PVC pipe. The potted tibia was rigidly fastened to a servohydraulic mechanical testing machine's vertical actuator (Fig. 1) by inserting it into an attachment cup with set screws. The Achilles tendon was dissected and exposed enough for a liquid nitrogen freeze clamp to clamp onto it. A steel cable ran vertically from the freeze clamp, over a pulley, and attached to a pneumatic cylinder with a load cell. This pulley setup created a physiologic line-of-action of the tendon tension. A pressure regulator controlled the amount of Achilles tension. The plantar surface of each specimen rested on a horizontal Emed pressure mat (novel, Munich, Germany). Fastened underneath the pressure mat, an axial load cell on a horizontal bearing measured the axial load (ground reaction force) (Fig. S1). During axial loading, the horizontal bearing

allowed the specimen to settle in a more natural orientation by removing any constraint in the horizontal plane.

The foot was held in a neutral position as it was initially lowered onto the pressure mat, which combined with the aforementioned horizontal bearing helped to minimize any contortion of the foot during testing. The tibia was translated down until a ground reaction force of 400 N was reached. Anatomical landmarks were detected by manually pressing on the pressure mat at each metatarsal, posterior point of heel and lateral, and medial forefoot. With the ground reaction force controlled to 400 N in all loading conditions, Achilles tendon force was increased as described below. Plantar pressures were recorded for each desired force condition. Average pressures, peak pressures, and contact areas were obtained and calculated using the Emed pressure mat and software. Pressures were segmented into first, second, and third adjacent metatarsal zones using the software.

### Surgeries

All surgeries were performed by the senior foot and ankle fellowship-trained orthopaedic surgeon or by a clinical foot and ankle fellow under his supervision. As we previously described in additional detail,<sup>17</sup> for the distal modified oblique osteotomy, the second metatarsal head was exposed after a 3 cm incision was made over the metatarsophalangeal joint. A classic distal metatarsal oblique osteotomy was performed using a 1 mm thick bladed micro-sagittal saw, parallel to the floor, starting 2 mm distal to the articular cartilage. Then, a second cut was made 3 mm proximal and parallel to the first osteotomy line. The resected piece was removed and parallelism of the surface cuts was then checked for accuracy. A cannulated 2.4 mm screw was used



**Figure 1.** A schematic drawing showing the second metatarsal osteotomies and plantar fascia release, as well as the mechanical foot loading setup. The foot was lowered onto the pressure mat while in a neutral position, and a bearing (not shown) under the force plate removed constraint in the horizontal plane (photograph provided in Fig. S1). The tibia was pressed down to induce a ground reaction force of 400 N, with 0, 300, or 600 N force simultaneously applied to the Achilles tendon.

to fix the osteotomy (Fig. 1). This double layer modification as described earlier for simultaneous shortening and dorsal translation achieves a more anatomical shortening without plantar translation of the metatarsal head.<sup>5</sup>

For the proximal oblique dorsiflexion osteotomy, the proximal third of the second metatarsal including the tarsometatarsal joint was exposed with a 3 cm dorsal incision. Starting 1 cm distal to the joint line, a 45-degree osteotomy was performed in proximal-to-distal direction using the micro sagittal saw with the same blade. A ruler was used to locate the second osteotomy line, which was 3 mm distal to the first cut. After the second osteotomy was completed, the parallel bony wedge was removed. The osteotomy was then closed and fixed with one cannulated 2.4 mm screw (Fig. 1).

#### Loading and Plantar Fascia Release

Pressure measurements were recorded for 0, 300, and 600 N Achilles force after either distal modified or proximal osteotomy of the second metatarsal (only 0 and 600 N were analyzed with hypothesis testing). Then the plantar fasciotomy was performed in all specimens. A 3 cm incision was made on the medial side of the foot in line with the proximal plantar fascia insertion. The plantar fascia was then visualized and a complete fascia release was performed using a surgical scissor. Pressure measurements were repeated for the three Achilles forces after plantar fascia release.

#### Statistics

Differences in average pressures, peak pressures, and contact areas were determined between the post-osteotomy condition and the post-plantar fascia release condition within each foot. Paired *t*-tests were used to test if the mean difference in average and peak pressures (for each osteotomy group, metatarsal, and 0 and 600 N Achilles loading conditions) was significantly different than zero, with significance set at  $p < 0.05$ .

### RESULTS

Effects of plantar fascia release may depend on which type of osteotomy was performed beforehand. Results are presented first for specimens with the modified distal osteotomy, then for specimens with proximal osteotomy. Plantar fascia release following modified distal osteotomy resulted in significant increases in average and peak pressures beneath the second metatarsal, relative to the condition pre-fascia release (post-osteotomy) (Fig. 2). Average pressures under the second metatarsal during 0 N Achilles loading were increased by an average of  $11.8 \pm 9.4$  kPa ( $p = 0.028$ ). Peak pressures were significantly increased under the 0 and 600 N Achilles loading conditions, with increases of  $26.7 \pm 20.7$  kPa ( $p = 0.025$ ) and  $66.7 \pm 43.8$  kPa ( $p = 0.014$ ) for 0 and 600 N Achilles force, respectively. Contact area changes associated with fascia release in these specimens are provided in Supplementary Figure S2.

Conversely, plantar fascia release following proximal osteotomy led to significant decrease in average pressure under the second metatarsal during 600 N of Achilles load (Fig. 2). This decrease averaged  $-14.2 \pm 11.1$  kPa ( $p = 0.001$ ).

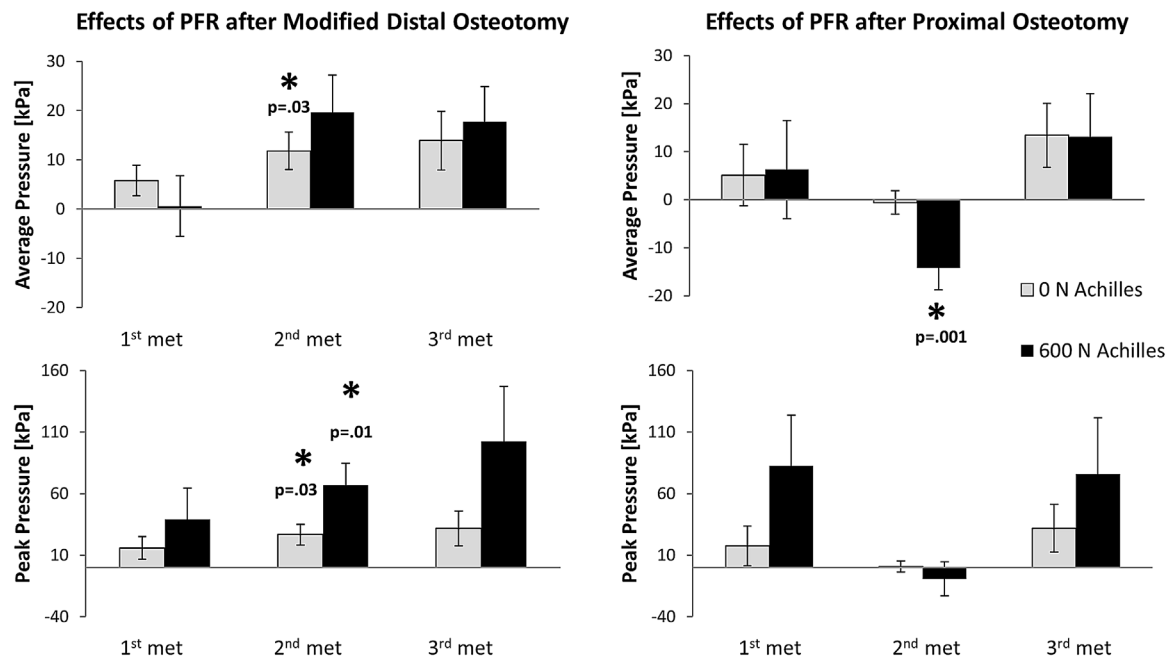
Additional non-significant trends were determined for these specimens. Average and peak pressures under the first and third metatarsals in these specimens showed an average increase following plantar fasciotomy after either osteotomy, under 0 and 600 N Achilles loading conditions, although not reaching statistical significance (Fig. 2). Average pressure under the 2nd metatarsal for the distal osteotomy group in these specimens for 600 N Achilles force increased an average of  $19.6 \pm 18.7$  kPa ( $p = 0.050$ ), although not considered statistically significant. Additionally, pressure changes tended to be magnified for increasing levels of Achilles force in these samples (Fig. 2).

### DISCUSSION

Plantar fasciotomy following second metatarsal osteotomies created mixed results in our study (Fig. 2). It caused a further decrease in peak metatarsal pressure underneath the second metatarsal after the proximal dorsiflexion osteotomy. Interestingly plantar fasciotomy added to the distal metatarsal osteotomy group showed an increase in peak metatarsal pressure underneath the second metatarsal. The findings of this biomechanical study help us in understanding the effect of plantar fascia release on metatarsal pressures in the setting of common metatarsal osteotomies performed for the treatment of metatarsalgia. Our results indicate that fasciotomy should generally not be added to distal metatarsal osteotomy in the treatment of metatarsalgia.

Jahss discussed that plantar fasciotomy release has no effect on biomechanics other than mild flattening of the arch.<sup>11</sup> Others reported that plantar fasciotomy influenced tarsal bone position significantly by destabilizing multiple intertarsal joints.<sup>18</sup> Plantar fascia release has been reported to shift the peak stress from the third to second metatarsal bone and increases the plantar ligament stress on the cuboid. Therefore, surgical release of plantar fascia should be well planned to decrease the risk of arch instability and lateral column pain due to increased overload.<sup>19,20</sup> Although we performed a complete release of the plantar fascia, we observed minor changes in the arch with no collapse of the foot, which correlates with prior studies.<sup>21</sup> Gefen reported that removal of the plantar fascia elevated bending loads on the tarsal bones, and thereby, increased the dorsal compression stresses. He suggested that plantar fasciotomy decreased the load-bearing and shock-attenuation capabilities of the foot, which increase the chance of having metatarsal stress fractures.<sup>22</sup> These findings correlate with our results for the distal oblique osteotomy group but not with the proximal oblique dorsiflexion osteotomy group results.

Plantar fascia has anatomical attachments to lesser metatarsophalangeal joint lines, and acts as a sling under the metatarsal heads and helps to distribute plantar pressures (Fig. 1). Sharkey et al. showed plantar fascia release would cause unrestrained dorsiflexion of the metatarsophalangeal joints pulling the



**Figure 2.** Changes in pressures associated with plantar fascia release following either modified distal or proximal osteotomy of the second metatarsal. Differences are relative to the pre-fascia release, post-osteotomy condition. \*Indicates mean significantly different than zero based on paired *t*-test ( $p < 0.05$ ). Error bars indicate  $\pm$  standard error.

released fascia and associated plantar tissues toward the toes, displacing these tissues relative to the metatarsal heads.<sup>21</sup> This pathologic mechanism may help explain our finding of increased plantar pressure underneath the metatarsal heads after plantar fasciotomy in the distal oblique osteotomy group.

Plantar fascia, on the other hand does not have any anatomical attachment to metatarsals proximally where the proximal dorsiflexion osteotomies were performed (Fig. 1). The metatarsal pressure decrease in the proximal dorsiflexion group may be partly explained by this anatomical difference, as plantar fasciotomy would not directly affect the proximal osteotomy but rather decrease the pull on metatarsal heads distally. In the distal osteotomy, the metatarsal head was shifted directly posteriorly which may have lessened the fascia passive tension and influence of the fascia on forefoot biomechanics. Conversely in the proximal osteotomy the metatarsal shift was oblique with a smaller posterior shift of the metatarsal head, and potentially smaller effects on plantar fascia tension.

Effects of plantar fascia release are likely dependent on forces acting from the Achilles tendon. A recent study showed that plantar fascia has an anatomical relationship with the paratenon of the Achilles tendon, and triceps surae structures could be involved in plantar fascia pathologies.<sup>15</sup> Other authors showed that gastrocnemius lengthening would have therapeutic effects on plantar heel pain and metatarsalgia, supporting use of this procedure by many foot and ankle surgeons.<sup>23,24</sup>

There are some limitations in our study. We tested a limited number of six matched pairs of cadaveric

feet; the study was likely not adequately powered and no clinically meaningful effect size was stated. Non-significant trends in our samples are described in the last paragraph of the Results; most notably, first and third metatarsal pressures increased on average in these specimens following fasciotomy after either osteotomy. Correction for multiple hypothesis testing was not performed, increasing the possibility of false significant findings when considering this exploratory study as a whole. Normal cadaver specimens without known metatarsalgia were tested. We also did not load the extrinsic or intrinsic muscles of the foot and ankle other than Achilles tendon. We did not test our samples in full heel raise position, but 600 N Achilles applied force was larger than an average Achilles pull; in fact we observed that the heel pad almost raised from the force plate at maximum pull which correlates with heel raise and heel plantar pressure approached to zero.<sup>25</sup> The applied forces in our study could be different than natural loading cycle, therefore further clinical studies are warranted to show the functional outcome of plantar fascia in conjunction with osteotomies in metatarsalgia patients.

In conclusion, the findings of this study showed that plantar fascia release causes substantial increase in second metatarsal pressures when added to the most commonly performed distal metatarsal osteotomies for the treatment of metatarsalgia, decreasing the effectiveness of these procedures. Interestingly if added to the proximal metatarsal osteotomy, plantar fascia release appears to accentuate the effect of the procedure by further decreasing the metatarsal

pressures. Future clinical studies are needed to confirm our findings in a clinical setting.

## AUTHORS' CONTRIBUTIONS

Umur Aydogan was the lead clinician in the study and involved in planning, surgeries, writing, and editing of the manuscript. Gregory Lewis was involved in planning, biomechanical loading design, data analysis, and writing, and editing of the manuscript. Evan Roush was involved in biomechanical setup, testing, and drafting parts of the manuscript. Blake Moore was involved in performing the surgery and testing of the specimens. Seth Andrews was involved in biomechanical setup, testing, and data analysis. All authors have read and approved the final submitted manuscript.

## REFERENCES

- Coughlin MJ. 2000. Common causes of pain in the forefoot in adults. *J Bone Joint Surg Br* 82:781–790.
- Espinosa N, Maceira E, Myerson MS. 2008. Current concept review: metatarsalgia. *Foot Ankle Int* 29:871–879.
- Fuhrmann RA, Roth A, Venbrocks RA. 2005. [Metatarsalgia. Differential diagnosis and therapeutic algorithm]. *Orthopade* 34:767–768, 769–772, 774–765.
- Barouk LS. 1996. [Weil's metatarsal osteotomy in the treatment of metatarsalgia]. *Orthopade* 25:338–344.
- Jarde O, Hussenot D, Vimont E, et al. 2001. [Weil's cervicocapital osteotomy for median metatarsalgia. Report of 70 cases]. *Acta Orthop Belg* 67:139–148.
- Trnka HJ, Nyska M, Parks BG, et al. 2001. Dorsiflexion contracture after the weil osteotomy: results of cadaver study and three-dimensional analysis. *Foot Ankle Int* 22:47–50.
- Giannini S, Ceccarelli F, Benedetti MG, et al. 2002. Surgical treatment of adult idiopathic cavus foot with plantar fasciotomy, naviculocuneiform arthrodesis, and cuboid osteotomy. A review of thirty-nine cases. *J Bone Joint Surg Am* 84-A:62–69.
- Faldini C, Traina F, Nanni M, et al. 2015. Surgical treatment of cavus foot in Charcot-Marie-tooth disease: a review of twenty-four cases: AAOS exhibit selection. *J Bone Joint Surg Am* 97:e30.
- Scranton PE, Jr. 1980. Metatarsalgia: diagnosis and treatment. *J Bone Joint Surg Am* 62:723–732.
- Hicks JH. 1954. The mechanics of the foot. II. The plantar aponeurosis and the arch. *J Anat* 88:25–30.
- Jahss MH. 1991. Miscellaneous soft tissue lesions. Disorders of the foot and ankle, 2nd ed. Philadelphia: WB Saunders Company. p 1514–1539.
- Gould N. 1984. Surgery in advanced Charcot-marie-tooth disease. *Foot Ankle* 4:267–273.
- Kim JY, Hwang S, Lee Y. 2012. Selective plantar fascia release for nonhealing diabetic plantar ulcerations. *J Bone Joint Surg Am* 94:1297–1302.
- Erdemir A, Hamel AJ, Fauth AR, et al. 2004. Dynamic loading of the plantar aponeurosis in walking. *J Bone Joint Surg Am* 86-A:546–552.
- Stecco C, Corradin M, Macchi V, et al. 2013. Plantar fascia anatomy and its relationship with Achilles tendon and paratenon. *J Anat* 223:665–676.
- Carlson RE, Fleming LL, Hutton WC. 2000. The biomechanical relationship between the tendoachilles, plantar fascia, and metatarsophalangeal joint dorsiflexion angle. *Foot Ankle Int* 21:18–25.
- Aydogan U, Moore B, Andrews SH, et al. 2015. Comparison of proximal and distal oblique second metatarsal osteotomies with varying Achilles tendon tension: biomechanical study in a cadaver model. *J Bone Joint Surg Am* 97:1945–1951.
- Kitaoka HB, Luo ZP, An KN. 1997. Effect of plantar fasciotomy on stability of arch of foot. *Clin Orthop Relat Res* 344:307–312.
- Cheung JT, Zhang M, An KN. 2004. Effects of plantar fascia stiffness on the biomechanical responses of the ankle-foot complex. *Clin Biomech (Bristol, Avon)* 19:839–846.
- Davies MS, Weiss GA, Saxby TS. 1999. Plantar fasciitis: how successful is surgical intervention? *Foot Ankle Int* 20:803–807.
- Sharkey NA, Donahue SW, Ferris L. 1999. Biomechanical consequences of plantar fascial release or rupture during gait. Part II: alterations in forefoot loading. *Foot Ankle Int* 20:86–96.
- Gefen A. 2002. Gastrocnemius shortening and heel pain. *J Biomech* 35:629–637.
- Solan MC, Carne A, Davies MS. 2014. Gastrocnemius shortening and heel pain. *Foot Ankle Clin* 19:719–738.
- Cazeau C, Stiglitiz Y. 2014. Effects of gastrocnemius tightness on forefoot during gait. *Foot Ankle Clin* 19:649–657.
- Fukunaga T, Kubo K, Kawakami Y, et al. 2001. In vivo behaviour of human muscle tendon during walking. *Proc Biol Sci* 268:229–233.

## SUPPORTING INFORMATION

Additional supporting information may be found in the online version of this article.